

Differential Effect of Spinal Cord Injury and Functional Impairment on Human Brain Activation

A. CURT,¹ M. BRUEHLMEIER,² K.L. LEENDERS,^{2,3} U. ROELCKE,² and V. DIETZ¹

ABSTRACT

Reorganization of human brain function after spinal cord injury (SCI) has been shown in electrophysiological studies. However, it is less clear how far changes of brain activation in SCI patients are influenced by the extent of SCI (neuronal lesion) or the consequent functional impairment. Positron emission tomography ($[^{15}\text{O}]\text{-H}_2\text{O-PET}$) was performed during an unilateral hand movement in SCI patients and healthy subjects. SCI patients with paraplegia and normal hand function were compared to tetraplegic patients with impaired hand movements. Intergroup comparison between paraplegic patients and healthy subjects showed an increased activation of contralateral sensorimotor cortex (SMC), contralateral thalamus, ipsilateral superior parietal lobe, and bilateral cerebellum. In contrast to this, tetraplegic patients with impaired upper limb function revealed only a significant activation of supplementary motor area (SMA). Correlational analysis in the tetraplegic patients showed that the strength of hand movement was related to the activation of contralateral SMC. However, the severity of upper limb sensorimotor deficit was related to a reduced activation of contralateral SMA and ipsilateral cerebellum. The findings suggest that in paraplegic patients with normal hand function the spinal neuronal lesion itself induces a reorganization of brain activation unrelated to upper limb function. Compared to this, in tetraplegic patients changes of brain activation are related to the impaired upper limb function. Therefore, in patients with SCI a differential impact of spinal lesion and functional impairment on brain activation can be shown. The effect of impaired afferent feedback and/or increased compensatory use of non-impaired limbs in SCI patients needs further evaluation.

Key words: cortical reorganization; human; PET; sensorimotor function; spinal cord injury

INTRODUCTION

PATIENTS with a traumatic spinal cord injury (SCI) present an acutely acquired neurological disorder with functional deficits (para/tetraplegia) caudal to the spinal lesion due to the loss of supraspinal control. They mainly suffer from a circumscribed spinal cord lesion and reveal functional deficits due to the disconnection of efferent

motor and afferent sensory pathways between a part of the body and brain centers. This generates a special condition for the brain, as cortical sensory and motor centres are preserved, while the neurally disconnected part of the body is not able to perform the required functions and to give appropriate afferent feedback.

Electrophysiological studies in patients with lesions of the peripheral and central (spinal and supraspinal) ner-

¹ParaCare, Institute for Rehabilitation and Research, University Hospital Balgrist, Zürich, Switzerland.

²PET Program, Paul Scherrer Institute, Villigen, Switzerland.

³Department of Neurology, University Hospital, Groningen, Switzerland.

vous system have shown several changes of brain function after trauma (Cohen et al., 1991b; Green et al., 1998). These consist in an enlargement of sensorimotor cortical areas and changes of excitatory and inhibitory mechanisms of different cortical areas. In addition, positron emission tomography (PET) studies in stroke patients also revealed extensive changes of cortical and subcortical areas after brain damage (Weiller et al., 1993). These findings show that even the adult brain is still capable of profound reorganization of brain function.

The aim of the present study was to assess the reorganization of brain activation in patients after SCI. PET scans were performed in young patients after traumatic SCI suffering from complete para- or tetraplegia. PET activation studies ($[^{15}\text{O}]\text{-H}_2\text{O-PET}$) of the brain were performed during a controlled hand motor task. In order to distinguish between the influence of the spinal cord lesion in paraplegic patients and the extent of functional impairment on brain activation, paraplegic patients with normal and tetraplegic patients with impaired upper limb function were studied. The hypothesis was, that specific changes in brain activation occur either due to the spinal cord lesion or due to the extent of upper limb impairment.

MATERIALS AND METHODS

General Procedures and Subject Groups

Participants in this study included seven paraplegic (four male, three female; median age 32 years, range

23–40 years; time posttrauma: median 2.9 years, range 0.3–9.9 years) and seven tetraplegic patients (all male; median age 26 years, range 18–46 years; time posttrauma: median 4.7 years, range 0.5–8.5 yrs). For comparison, eight male healthy subjects with median age of 27 years (range 24–32 years) were examined in parallel as a control. The study was approved by the local Ethics Committee of the University Hospital Balgrist. Patients and control subjects gave their written consent to participate in the study. A full neurological examination was performed in patients and healthy subjects in order to exclude accompanying neurological disorders of the peripheral and central nervous system. No patient or healthy subject suffered from a psychiatric disorder or had a history of brain trauma. All subjects were right handed.

Clinical Assessment of Spinal Cord Injury

In the patients, the level and extent of SCI (motor and sensory deficit) was assessed according to the protocol of the American Spinal Injury Association (ASIA; Ditunno et al., 1994). The ASIA scoring system allows to perform a semi-quantitative assessment of the neurological deficits (maximum of motor scores = 100; maximum of sensory scores for each light touch and pin prick sensation = 112). The assessment of motor and sensory scores of the upper and lower limbs allows to describe the extent of SCI and the sensorimotor deficits (Table 1). All patients suffered a complete traumatic para- or tetraplegia and were in a stable–chronic clinical condition.

TABLE 1. CLINICAL DATA OF THE PARAPLEGIC AND TETRAPLEGIC SCI PATIENTS INCLUDED IN THE STUDY

<i>SCI patients</i>	<i>Level of lesion</i>	<i>ASIA motor scores</i>				<i>ASIA sensory score</i>	
		<i>Right arm (max 25)</i>	<i>Left arm (max 25)</i>	<i>Both legs (max 50)</i>	<i>Total (max 100)</i>	<i>Pin prick (max 112)</i>	<i>Light touch (max 112)</i>
Para 1	L 2	25	25	0	50	90	90
Para 2	T 11	25	25	0	50	72	72
Para 3	T 2	25	25	0	50	33	33
Para 4	T 12	25	25	0	50	76	76
Para 5	T 12	25	25	23	73	88	92
Para 6	T 6	25	25	0	50	52	52
Para 7	T 4	24	25	0	49	62	72
Tetra 1	C 7	21	21	0	42	30	30
Tetra 2	C 7	15	15	0	30	26	26
Tetra 3	C 5	13	13	0	26	23	44
Tetra 4	C 6	9	10	0	19	23	23
Tetra 5	C 5	7	6	0	13	22	68
Tetra 6	C 5	6	8	0	14	18	18
Tetra 7	C 5	1	2	0	3	16	16

Upper Limb Sensorimotor Deficit

The upper limb and hand function were scored on the basis of the ASIA upper limb motor (maximum motor points 50) and sensory scores (maximum sensory points 32). All paraplegic patients had a full upper limb motor and sensory score, while all tetraplegic patients had reduced motor and sensory scores (Table 1). All tetraplegic patients showed at least a severe impairment of hand function (i.e., complete paralysis of the abductor pollicis brevis and abductor digiti minimi muscles, and sensory deficits of T1/C8 dermatomes) due to the cervical level of spinal cord lesion.

Motor Task

In all subjects a controlled and voluntary motor task of the right hand was performed. The subjects had to insert their right hand in a brace which was designed to measure the performed force during wrist extension. Therefore, a semiconductor installed in a bar was attached to the back of the hand and continuously recorded the force performed during wrist extension (integral force \times time; $N \times \text{sec}$). The patients and healthy subjects were instructed to perform a selective wrist extension of the right hand. To avoid additional movements of the proximal upper limb muscles, the lower arm was fixed within a splint. Therefore, the measured force could be attrib-

uted solely to wrist extension. As the movement rate of repetitive motor tasks is known to affect the cerebral activation the frequency of wrist extensions was held constant at 40 movements per minute, using a metronome as an external auditive cue (Schlaug et al., 1996; Blinkenberg et al., 1996). The results were recorded and calculated off line on a personal computer.

Positron Emission Tomography Recordings

[^{15}O]- H_2O -PET measurements of regional cerebral blood flow (rCBF) for correlation with neuronal activity were performed (Grafton et al., 1991). Brain images were obtained by a General Electric Advance PET scanner in the 3D-acquisition mode. Plasma radioactivity during the scans was not measured. Although this technique does not allow the calculation of the absolute cerebral blood flow, changes in rCBF relative to a global mean can be detected. Blood flow changes due to regional brain activation were assessed during repetitive wrist extension of the right hand. Motor activation and rest conditions were scanned twice. One minute prior to intravenous injection of 500 to 600 MBq [^{15}O]- H_2O , patients were instructed to close their eyes and to start with wrist extension. Data acquisition was started when the measured radioactivity within the head exceeded 50,000 counts per second (indicating the arrival of the tracer bolus in the brain) and

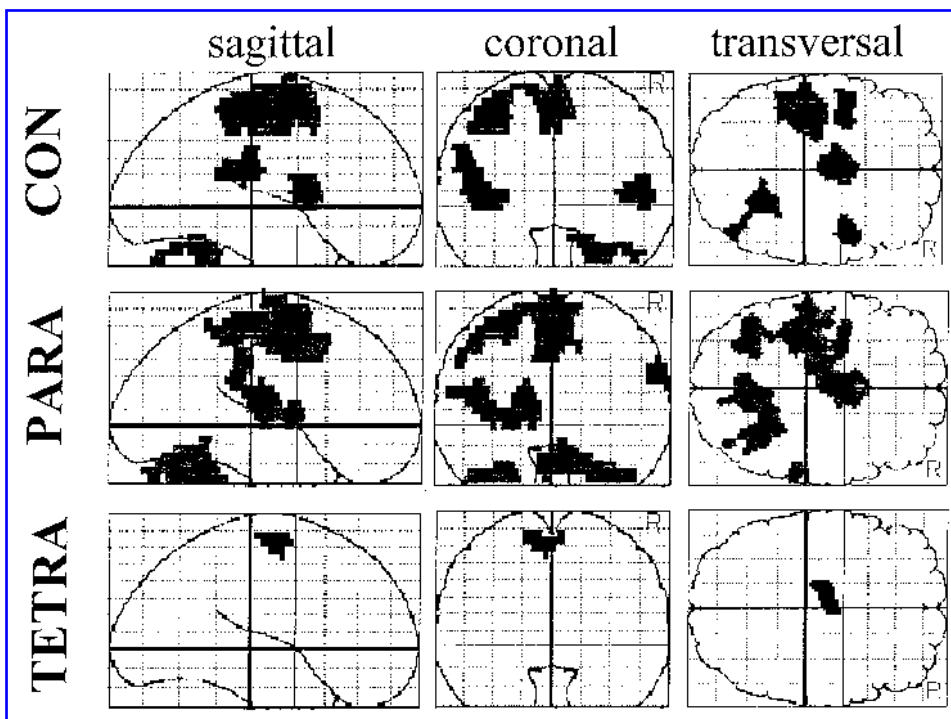


FIG. 1. SPM maps showing brain areas with significant rCBF increase during wrist extension in healthy subjects (CON), paraplegic (PARA), and tetraplegic (TETRA) SCI patients.

then lasted over 90 sec. To allow sufficient decay of resting radioactivity, the scanning was repeated after waiting 12 min. Images were reconstructed, controlled for alignment, transformed into stereotactic space and smoothed using a Gaussian filter 10 mm FWHM (Talairach and Tournoux, 1988). After normalization of the images, statistical parametric mapping (SPM) between resting and movement conditions were made for all groups using SPM95 software on a SPARC station 2 (Friston et al., 1991).

Statistics

All results are presented as SPM maps showing significant increases in rCBF during motor performance. Identical thresholds (uncorrected $p < 0.001$) were used for activation maps of all three groups which were of similar size (Fig. 1). Therefore differences found for brain activation between groups are unlikely to be due to a difference in threshold effects. Furthermore, intergroup comparisons were done (SPM 95, corrected $p < 0.05$) to compare rCBF increases between healthy subjects and patients (see Table 3 below). For calculation of the influence of different extent of wrist extension and upper limb sensorimotor deficits on brain activation in tetraplegic patients, SPM correlational analysis ($p < 0.001$) was performed (Figs. 2 and 3). Comparison of the extent of wrist extension between the 3

groups of subjects were analysed by a Mann-Whitney test ($p < 0.05$).

RESULTS

Brain Activation During Hand Activation in Spinal Cord Injury Patients

Figure 1 and Table 2 show those brain areas activated by repetitive wrist extension in healthy subjects, para- and tetraplegic patients. In control subjects (CON) during wrist extension, there was a significant activation of the contralateral sensorimotor cortex (SMC), bilateral supplementary motor areas (SMA), ipsilateral cerebellum, and bilateral insular cortex. In para- and tetraplegic patients, the pattern of brain activation was strikingly different from that obtained in healthy subjects.

In paraplegic patients (PARA) compared to controls, there was an additional activation of the contralateral thalamus and cerebellum, bilateral cerebellum vermis, and ipsilateral parietal cortex, while no activation of ipsilateral insular cortex was found. Tetraplegic patients (TETRA) revealed a much less activation of brain areas compared to control subjects and paraplegic patients. Using the same level of significance as in CON and PARA, only contralateral SMA showed an increased activation.

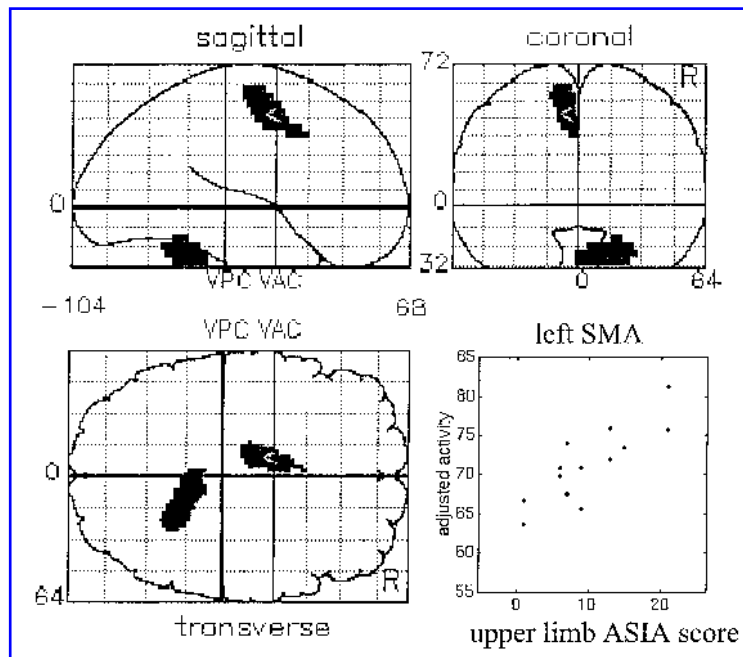


FIG. 2. SPM maps of tetraplegic patients (correlational analysis) showing brain areas, where rCBF increase of the brain correlated with upper limb sensorimotor scores. For demonstration, the scatter plot shows adjusted rCBF values of the contralateral SMA (left SMA; coordinates = x, 10; y, 6; z, 48).

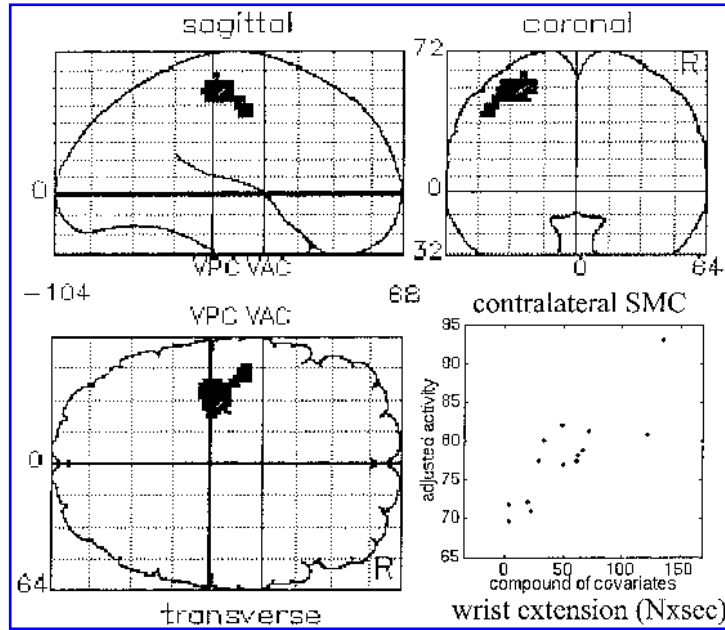


FIG. 3. SPM maps of tetraplegic patients (correlational analysis) showing brain areas, where rCBF increase of the brain correlated with the strength of wrist extension. The scatter plot shows adjusted rCBF values of contralateral SMC (left SMC; coordinates = $x, 30; y, 24; z, 52$) in relation to force of wrist extension (integral force \times time, $N \times \text{sec}$).

Brain Activation Related to Paraplegia

In order to assess the influence of SCI per se on brain activation during wrist extension statistical analysis using intergroup comparisons between CON /PARA were performed. Table 3 shows brain areas which were significantly more activated in paraplegic patients compared to control subjects. Motor performance was controlled in all groups by measuring the strength of wrist extension and was statistically equal in CON and PARA (CON mean 106.31 ± 44.64 SD $N \times \text{sec}$; PARA mean 107.75 ± 55.81 SD $N \times \text{sec}$). Therefore, group differences between CON and PARA could neither be attributed to a different amount of hand activation nor to an upper limb deficit, as all paraplegic patients had a normal upper limb function.

Brain Activation Related to Tetraplegia

The extent of upper limb functional impairment in tetraplegic patients was assessed by measuring strength of wrist extension and calculating the upper limb sensorimotor deficit. There was a significant reduction of force during wrist extension which could be performed by the tetraplegic patients (TETRA mean 48.65 ± 43.46 SD $N \times \text{sec}$) in contrast to control subjects and paraplegic patients. Also the upper limb sensorimotor scores were reduced in all tetraplegic patients in contrast to control subjects and paraplegic patients (Table 1). Therefore, in

tetraplegic patients two correlational analyses could be performed to assess the influence of upper limb functional impairment on brain activation. Figure 2 shows the SPM analysis with a significant correlation between the upper limb sensorimotor score and increased rCBF of contralateral SMA and ipsilateral cerebellum. Figure 3 shows SPM maps with an increase in rCBF in the contralateral SMC related to the strength of wrist extension ($p < 0.001$). Therefore, tetraplegic patients with an increased upper limb deficits showed a significantly reduced activation of contralateral SMA, SMC and ipsilateral cerebellum.

DISCUSSION

Electrophysiological and functional neuroimaging studies in humans suffering from lesions of the peripheral and central nervous system have shown, that even the adult brain is capable of extensive reorganization (Pons et al., 1991; Brasil-Neto et al., 1993). However, it is less clear in how far brain reorganization is induced by the neuronal lesion itself or by the consequent impairment of sensorimotor function. We performed a PET brain activation study during a hand motor task in patients suffering from different levels of a complete spinal cord injury with either normal (paraplegic patients) or impaired (tetraplegic patients) hand function. The present

TABLE 3. BRAIN AREAS, WHERE THE ACTIVATION (rCBF INCREASE) OF PARAPLEGIC PATIENTS EXCEEDS THE ACTIVATION OF CONTROLS ($p < 0.01$; x , y , AND z COORDINATES REFER TO THE STEREOTAXIC BRAIN ATLAS OF TALAIRACH AND TOURNOUX)

<i>Region</i>	<i>x</i>	<i>y</i>	<i>z</i>	<i>CON activation</i>	<i>PARA activation</i>	<i>Difference</i>
Left SMC (medial)	-14	-22	64	3.2%	12.1%	8.9%
Left thalamus	-12	-18	8	0.3%	11.6%	11.3%
Left cerebellum	-26	-72	-24	-1.1%	7.9%	9.0%
Right cerebellum	6	-70	-24	1.6%	6.8%	5.2%
Right superior parietal lobe	16	-54	60	-4.2%	6.6%	10.8%

study in SCI patients shows extensive changes in activation of cortical and subcortical brain centres during a hand motor task. Some of these changes are related to the condition of spinal cord lesion, as they occur during a hand motor task in paraplegic patients with normal hand function. Other changes in brain activation depend on the impaired upper limb function in tetraplegic patients.

Mapping studies with transcranial magnetic stimulation (TMS) and electroencephalographic recordings in SCI patients revealed changes of cortical sensorimotor areas (Topka et al., 1991). Preserved muscle groups proximal to the level of lesion in SCI patients showed an enlargement of the related cortical sensorimotor areas compared to healthy subjects (Levy et al., 1990). These changes corresponded to findings in patients suffering posttraumatic amputation of upper or lower limbs (Chen et al., 1998; Cohen et al., 1991a; Kew et al., 1994; Pascual-Leone et al., 1996).

The present study indicates extensive changes in activation of cortical and subcortical brain centres during hand movements in paraplegic patients, although they have a normal hand function. Paraplegic patients in contrast to healthy subjects showed an increased activation of contralateral SMC, thalamus, ipsilateral superior parietal lobe and bilateral cerebellum. These changes in brain activation during hand function should be induced by the condition of spinal cord lesion itself. The paraplegic patients studied experienced at no time after the trauma any impairment of upper limb function. The reorganization of brain activation might be induced by the extensive changes of afferent input from the body during the hand movements in paraplegic patients. The findings in humans corresponds to lesion studies in animals where peripheral nerve injuries induced profound reorganization of cortical and subcortical brain areas (Florence et al., 2000; Jones and Pons, 1998). Furthermore, extensive changes of cortical sensorimotor representation of not directly involved sensorimotor functions have been demonstrated like in changes of face representation after limb denervation (Elbert et al., 1994; Jain et al., 1997; Florence et al., 1998).

In addition to earlier studies, where changes in resting brain metabolism and brain activation in paraplegic patients could be shown, the influence of functional impairment on brain activation could be distinguished (Roelcke et al., 1997; Bruehlmeier et al., 1998). Here, we show that in tetraplegic patients the extent of wrist extension is still related to an increased activation of the contralateral SMC, although the motor strength is significantly reduced. This indicates, that the relationship between contralateral SMC activation and strength of hand movement is preserved in tetraplegic patients (Williamson et al., 1996; Allison et al., 2000). However the extent of upper limb sensorimotor deficit was related to a reduced activation of the contralateral SMA and ipsilateral cerebellum. These findings are in accordance to PET and functional magnetic resonance imaging (fMRI) studies where the relevance of afferent input on brain activation could be shown (Weiller, 1996; Lee et al., 1998). The reduced activation of contralateral SMA and ipsilateral cerebellum may be induced by the impaired afferent feedback, as the latter brain areas are also supposed to be involved in initiating/planning and controlling the performance of a motor task (Vidal et al., 1995; Kurata, 1992; Deiber et al., 1996). Furthermore, it has to be taken into account that impaired function of the autonomic nervous system after SCI might influence brain activation (Nowak et al., 1999).

The present study shows that the condition of spinal neuronal lesion in paraplegic patients induces a reorganization of brain activation which is unrelated to upper limb function, that is, during normal hand movements. In tetraplegic patients the impact of impaired upper limb function on brain activation can be distinguished. In how far the reorganization of brain activation is influenced by changes of afferent feedback should be studied using passive movements. Furthermore, the impact of increased compensatory use of non-impaired limbs in SCI patients needs further evaluation.

However the findings may help to improve the understanding of brain reorganization after SCI and to evaluate specific effects of rehabilitation on brain activation.

ACKNOWLEDGMENTS

This work was supported by the Swiss National Foundation (no. 3152-062025.00) and a grant of the Schweizerische Bankgesellschaft on behalf of a client. We thank the staff of the Nuclear Medicine Department, University Hospital Zurich, for assistance in performing the PET measurements.

REFERENCES

- ALLISON, J.D., MEADOR, K.J., LORING, D.W., FIGUEROA, R.E., and WRIGHT, J.C. (2000). Functional MRI cerebral activation and deactivation during finger movement. *Neurology* **54**, 135–142.
- BLINKENBERG, M., BONDE, C., HOLM, S., SVARER, C., ANDERSEN, J., PAULSON, O.B., and LAW, I. (1996). Rate dependency of regional cerebral activation during performance of a repetitive motor task: a PET study. *J. Cereb. Blood Flow Metab.* **16**, 794–803.
- BRASIL-NETO, J.P., VALLS-SOLE, J., PASCUAL-LEONE, A., et al. (1993). Rapid modulation of human cortical motor outputs following ischaemic nerve block. *Brain* **116**, 511–525.
- BRUEHLMEIER, M., DIETZ, V., LEENDERS, K.L., ROELCKE, U., MISSIMER, J., and CURT, A. (1998). How does the human brain deal with a spinal cord injury? *Eur. J. Neurosci.* **10**, 3918–3923.
- CHEN, R., CORWELL, B., YASEEN, Z., HALLET, M., and COHEN, L.G. (1998). Mechanisms of cortical reorganization in lower-limb amputees. *J. Neurosci.* **18**, 3443–3450.
- COHEN, L.G., BANDINELLI, S., FINDLEY, T.W., and HALLETT, W. (1991a). Motor reorganization after upper limb amputation in man. *Brain* **114**, 615–627.
- COHEN, L.G., ROTH, B.J., WASSERMANN, E.M., TOPKA, H., FUHR, P., SCHULTZ, J., and HALLETT, M. (1991b). Magnetic stimulation of the human cerebral cortex, an indicator of reorganization in motor pathways in certain pathological conditions. *J. Clin. Neurophysiol.* **8**, 56–65.
- DEIBER, M.P., IBANEZ, V., SADATO, N., and HALLETT, M. (1996). Cerebral structures participating in motor preparation in humans: a positron emission tomography study. *J. Neurophysiol.* **75**, 233–247.
- DITUNNO, J.F., YOUNG, W., DONOVAN, W.H., and CREASEY, G. (1994). The international standards booklet for neurological and functional classification of spinal cord injury. *Paraplegia* **32**, 70–80.
- ELBERT, T., FLOR, H., BIRBAUMER, N., KNECHT, S., HAMPSON, S., LARBIG, W., and TAUB, E. (1994). Extensive reorganization of the somatosensory cortex in adult humans after nervous system injury. *Neuroreport* **5**, 2593–2597.
- FLORENCE, S.L., TAUB, H.B., and KAAS, J.H. (1998). Large-scale sprouting of cortical connections after peripheral injury in adult macaque monkeys. *Science* **282**, 1117–1121.
- FLORENCE, S.L., HACKETT, T.A., and STRATA, F. (2000). Thalamic and cortical contribution to neural plasticity after limb amputation. *J. Neurophysiol.* **83**, 3154–3159.
- FRISTON, K.J., FRITH, C.D., LIDDLE, P.F., and FRACKOWIAK, R.S. (1991). Comparing functional (PET) images: the assessment of significant changes. *J. Cereb. Blood Flow Metab.* **11**, 690–699.
- GRAFTON, S.T., WOODS, R.P., MAZZIOTTA, J.C., and PHELPS, M.E. (1991). Somatotopic mapping of the primary motor cortex in humans: Activation studies with cerebral blood flow and positron emission tomography. *J. Neurophysiol.* **66**, 735–743.
- GREEN, J.B., SORA, E., BIALY, Y., RICAMATO, A., and THATCHER, R.W. (1998). Cortical sensorimotor reorganization after spinal cord injury: An electroencephalographic study. *Neurology* **50**, 1115–1121.
- JAIN, N., CATANIA, K.C., and KAAS, J.H. (1997). Deactivation and reactivation of somatosensory cortex after dorsal spinal cord injury. *Nature* **386**, 495–498.
- JONES, E.G., and PONS, T.P. (1998). Thalamic and brainstem contribution to large-scale plasticity of primate somatosensory cortex. *Science* **282**, 1121–1125.
- KEW, J.J.M., RIDDING, M.C., ROTHWELL, J.C., et al. (1994). Reorganization of cortical blood flow and transcranial magnetic stimulation maps in human subjects after upper limb amputation. *J. Neurophysiol.* **72**, 2517–2524.
- KURATA, K. (1992). Somatotopy in the human supplementary motor area. *TINS* **15**, 159–160.
- LEE, C.C., JACK, C.R., and RIEDERER, S.J. (1998). Mapping of the central sulcus with functional MR: Active versus passive activation tasks. *Am. J. Neuroradiol.* **19**, 847–852.
- LEVY, W.J., AMASSIAN, V.E., TRAAD, M., and CADWELL, J. (1990). Focal magnetic stimulation reveals motor cortical system reorganized in humans after traumatic quadriplegia. *Brain Res.* **510**, 130–134.
- NOWAK, M., OLSEN, K.S., LAW, I., HOLM, S., PAULSON, O.B., and SECHER, N.H. (1999). Command-related distribution of regional cerebral blood flow during attempted hand-grip. *J. Appl. Physiol.* **86**, 819–824.
- PASCUAL-LEONE, A., PERIS, M., TORMOS, J.M., PASCUAL, A.P., and CATALA, M.D. (1996). Reorganization of human cortical motor output maps following traumatic forearm amputation. *NeuroReport* **7**, 2068–2070.
- PONS, T.P., GARRAGHTY, P.E., OMMAYA, A.K., KAAS, J.H., TAUB, E., and MISHKIN, M. (1991). Massive reorganization of the primary somatosensory cortex after peripheral sensory deafferentation. *Science* **252**, 1857–1860.
- ROELCKE, U., CURT, A., OTTE, A., MISSIMER, J.,

- MAGUIRE, R.P., DIETZ, V., and LEENDERS, K.L. (1997). Influence of spinal cord injury on cerebral sensorimotor systems: a PET study. *J. Neurol. Neurosurg. Psychiatry* **62**, 61–65.
- SCHLAUG, G., SANES, J.N., THANGARAJ, V., DARBY, D.G., JANCKE, L., EDELMAN, R.R., and WARACH, S. (1996). Cerebral activation covaries with movement rate. *Neuroreport* **7**, 879–883.
- TALAIRACH, J., and TOURNOUX, P. (1988). *Co-Planar Stereotaxic Atlas of the Human Brain*. Georg Thieme, Stuttgart.
- TOPKA, H., COHEN, L.G., COLE, R.A., and HALLETT, M. (1991). Reorganization of corticospinal pathways following spinal cord injury. *Neurology* **41**, 1276–1283.
- VIDAL, F., BONNET, M., and MACAR, F. (1995) Programming the duration of a motor sequence: Role of the primary and supplementary motor areas in man. *Exp. Brain Res.* **106**, 339–350.
- WEILLER, C., RAMSAY, S.C., WISE, R.J., FRISTON, K.J., and FRACKOWIAK, R.S. (1993). Individual patterns of functional reorganization in the human cerebral cortex after capsular infarction. *Ann. Neurol.* **33**, 181–189.
- WEILLER C. (1996). Brain representation of active and passive movements. *Neuroimage* **4**, 105–110.
- WILLIAMSON, J.W., FRIEDMAN, D.B., MITCHELL, J.H., SECHER, N.H., and FRIBERG, L. (1996). Mechanisms regulating regional cerebral activation during dynamic handgrip in humans. *J. Appl. Physiol.* **81**, 1884–1890.

Address reprint requests to:

A. Curt, M.D.

ParaCare

Institute for Rehabilitation and Research

University Hospital Balgrist

CH-8008 Zürich, Switzerland

E-mail: acurt@balgrist.unizh.ch

This article has been cited by:

1. Xiang Yang Chen , Yi Chen , Lu Chen , Ann M. Tennissen , Jonathan R. Wolpaw . 2006. Corticospinal Tract Transection Permanently Abolishes H-Reflex Down-Conditioning in Rats. *Journal of Neurotrauma* **23**:11, 1705-1712. [[Abstract](#)] [[PDF](#)] [[PDF Plus](#)]
2. Jaivijay Ramu, Kurt H. Bockhorst, Kishore V. Mogatadakala, Ponnada A. Narayana. 2006. Functional magnetic resonance imaging in rodents: Methodology and application to spinal cord injury. *Journal of Neuroscience Research* **84**:6, 1235. [[CrossRef](#)]
3. Donatella Mattia, Febo Cincotti, Marco Mattiocco, Giorgio Scivoletto, Maria Grazia Marciani, Fabio Babiloni. 2005. Motor-related cortical dynamics to intact movements in tetraplegics as revealed by high-resolution EEG. *Human Brain Mapping* . [[CrossRef](#)]